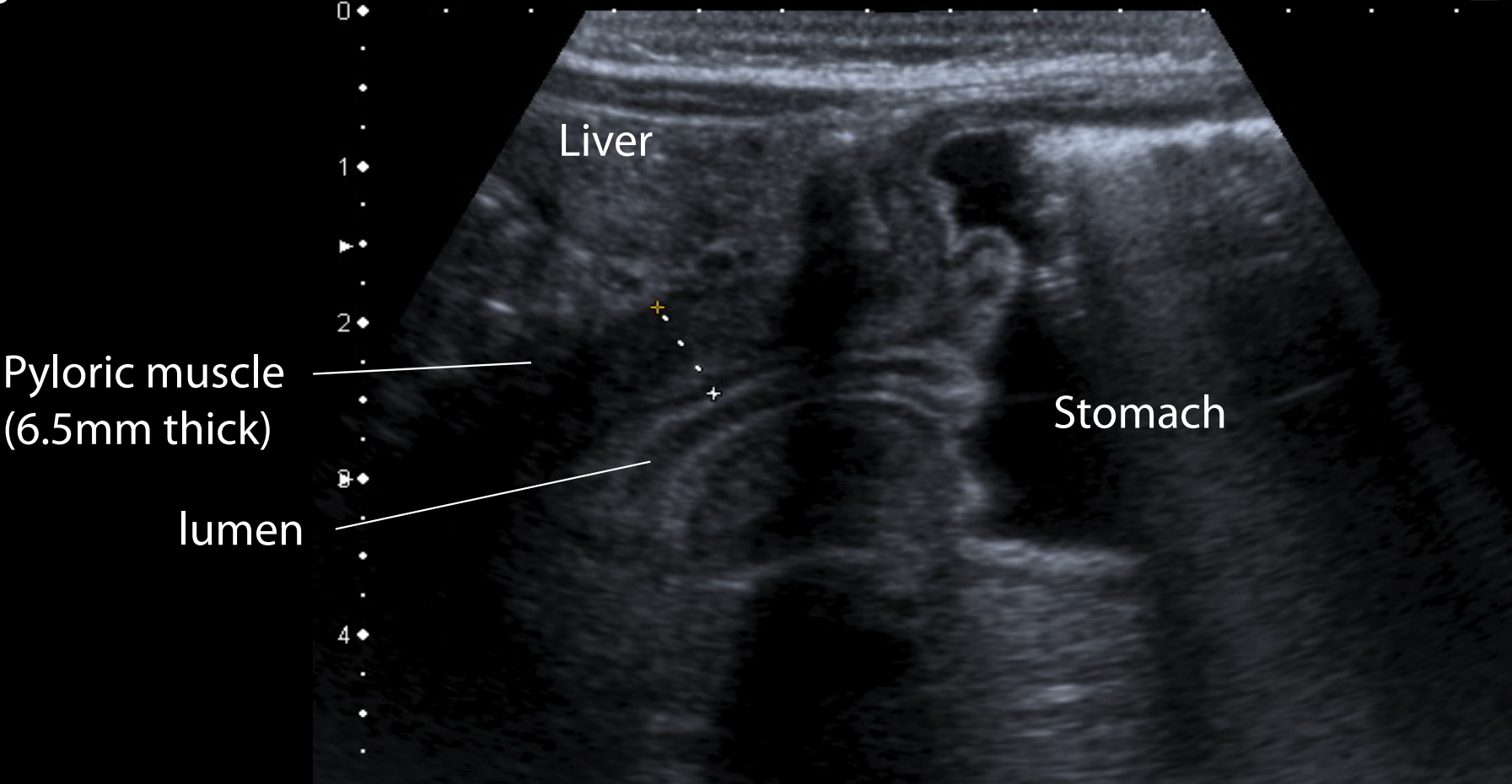


Ultrasound scan demonstrating pyloric stenosis in an 8 week old infant.

Longitudinal section



Transverse section

